

In Situ Anterior Vaginal Wall Sling for Treatment of Stress Urinary Incontinence

Extended Application and Further Experience

Mahmoud Mustafa,¹ Bassam S Wadie²

Introduction: Our aim was to evaluate the efficacy of utilizing in situ anterior vaginal wall sling in the treatment of stress urinary incontinence (SUI).

Materials and Methods: The study included 11 women with a median age of 50 years (range, 36 to 60 years) who were operated on during the period of November 2005 to August 2006. They were diagnosed with SUI and were operated on using placard-shaped in situ anterior vaginal wall sling technique. Nine patients underwent surgical treatment for the first time, while 2 patients had postoperative recurrent SUI. In all of the patients, urethral hypermobility with or without cystocele was observed. The mean follow-up period was 22.5 months (range, 17 to 28 months).

Results: Ten patients (90.9%) were considered cured and 1 (9.1%) started leakage of urine after 1 month during the postoperative period. One patient (9.1%) had urinary retention. Three patients (27.3%) had evidence of wound infection which was treated by appropriate oral medical therapy.

Conclusion: In situ anterior vaginal wall sling technique is accredited with a good success rate and low incidence of complications. It is easy to learn and cost-effective, making it a suitable technique for SUI. Longer follow-up and larger number of patients are needed before final conclusion could be drawn.

Keywords: stress urinary incontinence, suburethral slings, urologic surgical procedures, female

Urol J. 2009;6:35-9.
www.uj.unrc.ir

INTRODUCTION

In women with stress urinary incontinence (SUI) secondary to urethral hypermobility, the aim of surgery is to restore the proper position of the urethra and the bladder neck through a transvaginal or abdominal procedure. Many published studies in the past 5 years have promoted the results of recently introduced minimally invasive techniques adopted for treating SUI.⁽¹⁻⁵⁾ Tension-free vaginal tape (TVT) represents a well-established surgical procedure for the treatment of SUI. The technique, described in 1996

by Ulmsten and colleagues,⁽⁶⁾ is based on a midurethral prolene tape support, which is accepted worldwide as an easy-to-learn, effective, and safe surgical technique with low incidence of complications.⁽⁶⁻¹⁰⁾ However, a 5% to 15% failure rate after TVT was reported and many techniques were offered as alternatives,^(7,8,10,11) the results of some of which have remained far from optimum. Furthermore, TVT was reportedly associated with serious perioperative complications, despite its high efficacy.⁽¹⁾ As an attempt in a recent study to modify the

¹Osmaniye State Hospital, Urology Department, Osmaniye, Turkey
²Female Urology and Voiding Dysfunction, Urology and Nephrology Center, Mansoura University, Mansoura, Egypt

Corresponding Author:
Mahmoud Mustafa, MD
Department of Urology, Izmir Atatürk Teaching Hospital, Izmir, Turkey
Tel: +90 232 245 4545
Fax: +90 232 243 1530
E-mail: dr_mahmoud68@yahoo.com

Received May 2008
Accepted December 2008

technique to reach better outcomes, we reported encouraging results using *placard technique*, where we utilized in situ sling of the anterior vaginal wall for the treatment of SUI, especially in selective patients with an average body mass index.⁽¹²⁾ In the current study, we report our experience adopting the same technique as a first choice anti-incontinence procedure in all of our patients with SUI.

MATERIALS AND METHODS

Eleven women were scheduled for surgical treatment of SUI by placard-shaped anterior in situ vaginal wall sling between November 2005 and August 2006 at our center. Clinical examination revealed urethral hypermobility with or without cystocele. The diagnosis of SUI was based on a positive stress test and the presence of urethral hypermobility confirmed by cotton swab test. Stress urinary incontinence was defined as involuntary leakage on effort, exertion, sneezing, or coughing, and urge incontinence was defined as the complaint of involuntary leakage accompanied by or immediately preceded by urgency.⁽¹³⁾ Urethral hypermobility was assessed with Q-tip test. The degree of cystocele was assessed according to the Baden-Walker prolapse classification.⁽¹⁴⁾ Cystocele was observed in 10 patients with various grades; 3 patients had grade 3, 4 patients had grade 2, and 1 patient had grade 1 cystocele. Urodynamic tests were performed in patients who were not diagnosed with pure stress incontinence. Any patient suffered from urodynamically documented urge incontinence was excluded from the study. Of the study group, 2 patients had had prior anti-incontinence surgeries, both of whom had TVTs and were found to have bladder erosion and vaginal erosion, respectively. In the patient with bladder erosion of the tape, endoscopic excision of the tape was accomplished first, and when control cystoscopy revealed complete healing of the bladder mucosa, the patient was operated upon.⁽¹⁵⁾

The operation was performed under spinal or general anesthesia. In the lithotomy position, an 18-F Foley catheter was inserted and the bladder was evacuated. Then, a placard-shaped incision was made in the anterior vaginal wall (Figure 1),

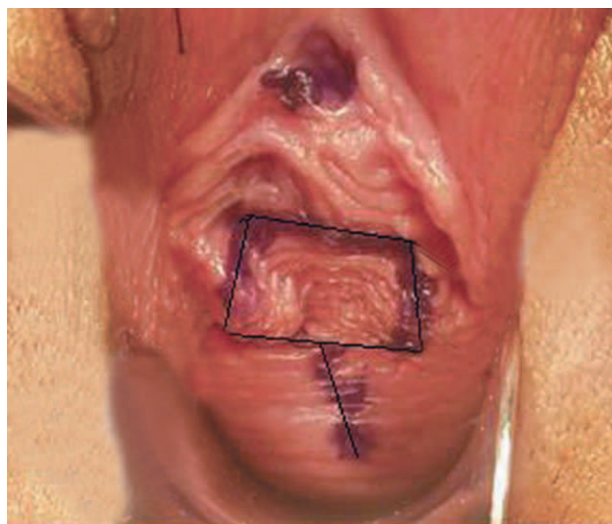


Figure 1. Schematic illustration of placard-shaped incision (black line) at the anterior vaginal wall.

and dissection of the vaginal flap was carried out to prepare in situ anterior vaginal wall sling (Figure 2). The length of midline incision at the anterior vaginal wall was determined according to the degree of cystocele. Then, the dissection at the lateral side of the in situ sling was done until the surgeon's index finger could be easily felt from the suprapubic area. A small transverse incision of 4 cm to 5 cm was made over the symphysis pubis without cutting the rectus fascia, and 2 suspension sutures of 1 polypropylene were inserted in

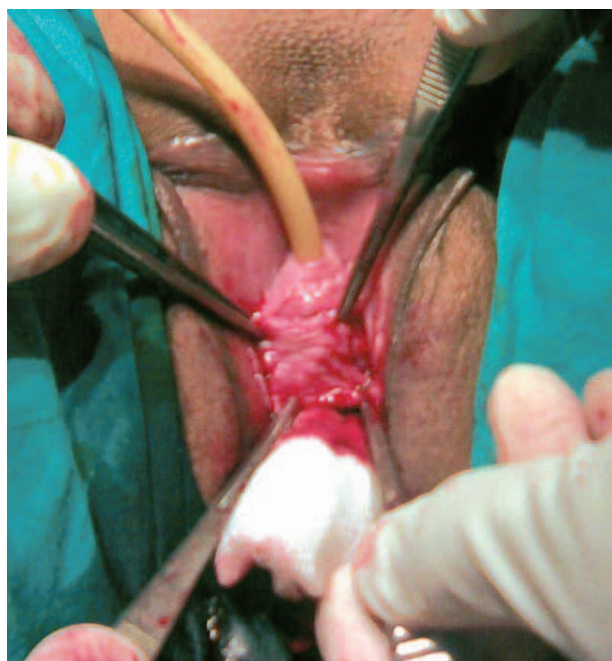

Figure 2. In situ vaginal sling prepared from the anterior vaginal wall after dissection of the vaginal flap was carried out.

the flap (Figure 3) and passed lateral to urethra. Before fixation of the suspension sutures to the periosteum of symphysis pubis, the bladder was filled with 250-mL to 300-mL isotonic solution. Manual pressure was applied to the suprapubic area to test for leakage, thus adjusting the tension of the sutures. Closure of the placard incision then followed over the in situ sling. Intraoperative cystoscopy was done to rule out bladder or urethral injury.

All of the patients were hospitalized for 1 to 2 days. The Foley catheter was left for 5 postoperative days. A vaginal sponge was placed at the end of the operation and removed 24 hours later. The operative time varied from 45 to 90 minutes (mean, 60 minutes). During the postoperative period, sexual intercourse and carrying heavy weights was discouraged for 2 months. All of the patients were followed at 1, 3, 6 postoperative months, and every 4 months thereafter. The mean follow-up period was 22.5 months (range, 17 to 28 months). Postvoid residual urine of 50 mL or less was considered as insignificant. Follow-up evaluation included self-made questionnaire assessment, physical examination with stress test, and postvoid residual measurement. Cure of SUI after the procedure was defined as the absence of any complaint

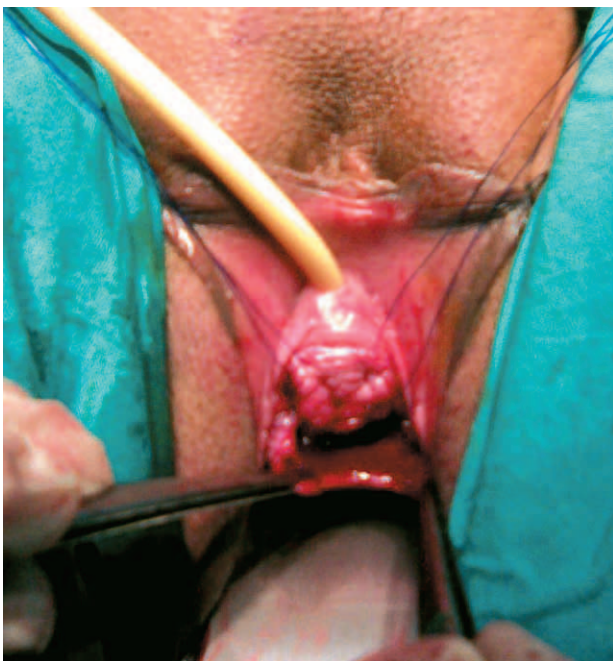

Figure 3. Two suspension sutures are placed at the lateral sides of the sling.

of leakage and the absence of leakage on stress testing. Improvement was defined as no urine loss on stress plus patients' report of some leakage but overall satisfaction. Therapeutic failure was considered in cases of sustained urinary stress incontinence.

RESULTS

Eleven patients with a median age of 50 years (range, 36 to 60 years) underwent in situ anterior vaginal wall sling surgical operation. One patient had retention (9.1%) after removal of the catheter which was resolved by extra 5 days of catheterization. Ten patients became totally continent (cure rate, 90.9%). One patient (9.1%) resumed incontinence after carrying heavy weight in the 1st month postoperatively. Three patients (27.3%) had evidence of wound sepsis in the form of suprapubic tenderness and redness, which was treated by oral antibiotics and nonsteroidal anti-inflammatory drugs. Three patients (27.3%) had temporary urgency without urge incontinence, starting at the 3rd postoperative week, which were improved by anti-muscarinic drugs for 3 weeks. There was no significant postvoid residual urine detected by real-time abdominal ultrasonography after catheter removal.

DISCUSSION

The current view in incontinence surgery is in favor of pubovaginal fascial sling over traditional abdominal colposuspension techniques, as the results of the former is much better at long-term as regards efficacy, morbidity, hospital stay, and costs to public healthcare.^(2,16,17) Since its introduction, TVT has been found to be as effective as fascial sling.⁽¹⁸⁾ However, many publications reported no significant differences between various midurethral sling procedures.^(19,20) The success rate of midurethral sling in short-term and long-term follow-up varied from 85% to 95%.^(7,8,10,11,18) Although TVT is simple and minimally invasive, there were reportedly serious complications such as bowel perforation, retropubic hematoma, and venous injury.⁽²¹⁻²⁵⁾ Urinary retention, bladder perforation, urethral erosion and wound infection were reported in 2.3%, 3.8%, 0.07%, and 0.8% of the operated patients, respectively.⁽⁸⁾ In our

technique, the success rate (90.9%) did not differ from the reported success rates of other techniques. Cost effectiveness and low incidence of urethral or bladder erosion are the most important potential advantages of this technique. It also adjoins reasonable success as regards cure of incontinence to good feasibility of cystocele correction. The hospitalization period was short with no clinically significant morbidity in the postoperative period. However, the rates of complications in terms of urinary retention and wound infection were found to be higher than the rates reported in literature, which might be due to low number of patients included in the early experience. Lo and coworkers reported that the immobilization of the urethra, as a result of fibrosis around the mesh, which is seen in about 26.8% of secondary cases of TVT, seems to be a risk factor for failure of reconstruction in the re-operated cases.⁽²⁶⁾ However, in our technique, the degree of fibrosis around the urethra was expected to be less than that of TVT as there was no exogenous material used.

The use of this procedure in secondary cases of SUI seems to be acceptable. Of 2 patients who had in situ flap as a re-do, both were cured. However, performing this technique for secondary cases may carry some difficulties in preparing the in situ sling due to fibrosis because of the previously done surgeries. The place of urodynamic study in patients with pure urodynamic SUI is not universally accepted. While some studies emphasize its importance,^(27,28) others are not in support of routine urodynamic study in such patients.^(29,30) In our study, patients who were diagnosed with pure SUI were not urodynamically tested, because we believe that urodynamic study is not necessary in such cases.

Backing vaginal sponge with povidone iodine and antibiotics cream decreases vaginal infection and supports the sling in the early postoperative period. Moreover, advising sexual abstinence and avoiding heavy lifting for a sufficient postoperative period helps in improving the outcome of the surgery. In general, we would like to underline that the learning curve of the surgeon is in such kinds of operation as a crucial issue in determining the success rate.

CONCLUSION

In situ anterior vaginal wall sling technique for treatment of SUI is simple and cost effective, while it has a low incidence of complications in the postoperative period. The mid-term success rate seems to be satisfactory; therefore, this procedure can be a reasonable option for SUI. Longer follow-up and a larger sample size are needed before final conclusion could be drawn.

CONFLICT OF INTEREST

None declared.

REFERENCES

1. Leuret T, Lugagne PM, Herve JM, et al. Evaluation of tension-free vaginal tape procedure. Its safety and efficacy in the treatment of female stress urinary incontinence during the learning phase. *Eur Urol.* 2001;40:543-7.
2. Appell RA. The use of bone anchoring in the surgical management of female stress urinary incontinence. *World J Urol.* 1997;15:300-5.
3. Chaikin DC, Rosenthal J, Blaivas JG. Pubovaginal fascial sling for all types of stress urinary incontinence: long-term analysis. *J Urol.* 1998;160:1312-6.
4. Cross CA, Cespedes RD, McGuire EJ. Our experience with pubovaginal slings in patients with stress urinary incontinence. *J Urol.* 1998;159:1195-8.
5. Chaikin DC, Blaivas JG, Rosenthal JE, Weiss JP. Results of pubovaginal sling for stress incontinence: a prospective comparison of 4 instruments for outcome analysis. *J Urol.* 1999;162:1670-3.
6. Ulmsten U, Henriksson L, Johnson P, Varhos G. An ambulatory surgical procedure under local anesthesia for treatment of female urinary incontinence. *Int Urogynecol J Pelvic Floor Dysfunct.* 1996;7:81-5.
7. Olsson I, Kroon U. A three-year postoperative evaluation of tension-free vaginal tape. *Gynecol Obstet Invest.* 1999;48:267-9.
8. Kuuva N, Nilsson CG. A nationwide analysis of complications associated with the tension-free vaginal tape (TVT) procedure. *Acta Obstet Gynecol Scand.* 2002;81:72-7.
9. Paraiso MF, Muir TW, Sokol AI. Are midurethral slings the gold standard surgical treatment for primary genuine stress incontinence? *J Am Assoc Gynecol Laparosc.* 2002;9:405-7.
10. Waetjen LE, Subak LL, Shen H, et al. Stress urinary incontinence surgery in the United States. *Obstet Gynecol.* 2003;101:671-6.
11. Neuman M. Tension-free vaginal tape bladder penetration and long-lasting transvesical Prolene material. *J Pelvic Med Surg.* 2004;10:307-9.
12. Mustafa M, Wadie BS. Placard-shaped in situ vaginal wall sling for the treatment of stress urinary

- incontinence. *Int J Urol*. 2006;13:132-4.
13. Abrams P, Cardozo L, Fall M, et al. The standardisation of terminology of lower urinary tract function: report from the Standardisation Subcommittee of the International Continence Society. *Neurourol Urodyn*. 2002;21:167-78.
 14. Baden WF, Walker TA. *Surgical repair of vaginal defects*. Philadelphia: JB Lippincott; 1992.
 15. Mustafa M, Wadie BS. Bladder erosion of tension-free vaginal tape presented as vesical stone; management and review of literature. *Int Urol Nephrol*. 2007;39:453-5.
 16. Coucke K, Kesteloot K. A comparison of health care financing policies for incontinence products in European countries. *Eur Urol*. 2000;37:36-42.
 17. Albo ME, Richter HE, Brubaker L, et al. Burch colposuspension versus fascial sling to reduce urinary stress incontinence. *N Engl J Med*. 2007;356:2143-55.
 18. Wadie BS, Edwan A, Nabeeh AM. Autologous fascial sling vs polypropylene tape at short-term followup: a prospective randomized study. *J Urol*. 2005;174:990-3.
 19. Abdel-Fattah M, Barrington JW, Arunkalaivanan AS. Pelvic pubovaginal sling versus tension-free vaginal tape for treatment of urodynamic stress incontinence: a prospective randomized three-year follow-up study. *Eur Urol*. 2004;46:629-35.
 20. Tseng LH, Wang AC, Lin YH, Li SJ, Ko YJ. Randomized comparison of the suprapubic arc sling procedure vs tension-free vaginal taping for stress incontinent women. *Int Urogynecol J Pelvic Floor Dysfunct*. 2005;16:230-5.
 21. Volkmer BG, Nessler T, Rinnab L, Schradin T, Hautmann RE, Gottfried HW. Surgical intervention for complications of tension-free vaginal tape procedure. *J Urol*. 2003;169:570-4.
 22. Wyczolkowski M, Klima W, Piasecki Z. Reoperation after complicated tension-free vaginal tape procedures. *J Urol*. 2001;166:1004-5.
 23. Sweat SD, Itano NB, Clemens JQ, et al. Polypropylene mesh tape for stress urinary incontinence: complications of urethral erosion and outlet obstruction. *J Urol*. 2002;168:144-6.
 24. Jorion JL. Endoscopic treatment of bladder perforation after tension-free vaginal tape procedure. *J Urol*. 2002;168:197.
 25. Tsivian A, Kessler O, Mogutin B, et al. Tape related complications of the tension-free vaginal tape procedure. *J Urol*. 2004;171:762-4.
 26. Lo TS, Horng SG, Chang CL, Huang HJ, Tseng LH, Liang CC. Tension-free vaginal tape procedure after previous failure in incontinence surgery. *Urology*. 2002;60:57-61.
 27. Summitt RL, Jr., Stovall TG, Bent AE, Ostergard DR. Urinary incontinence: correlation of history and brief office evaluation with multichannel urodynamic testing. *Am J Obstet Gynecol*. 1992;166:1835-40.
 28. Weidner AC, Myers ER, Visco AG, Cundiff GW, Bump RC. Which women with stress incontinence require urodynamic evaluation? *Am J Obstet Gynecol*. 2001;184:20-7.
 29. Hastie KJ, Moisey CU. Are urodynamics necessary in female patients presenting with stress incontinence? *Br J Urol*. 1989;63:155-6.
 30. Lagro-Janssen AL, Debruyne FM, van Weel C. Value of the patient's case history in diagnosing urinary incontinence in general practice. *Br J Urol*. 1991;67:569-72.